




# Ask the Lab

Stephen D. Killian, CDT



## Cont'd Discussion

### \* Five Photos

## Cosmetic Dentistry Photos

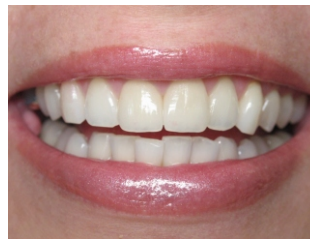for communicating and consulting with the Ceramist

**Q:** Steve, please describe the five photos you need for a large anterior case?

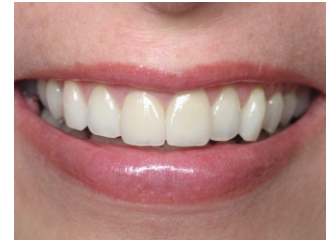**A:** The sample photographs shown below will convey all essential anatomical aspects of the desired finished restorations, such as incisal length, tooth form, incisal edge position (over-jet and over-bite), occlusal plane (Curve of Spee and Curve of Wilson), labial inclination of anteriors, the buccal corridor (buccal bulk of posteriors), gingival height of contour, and incisal and gingival embrasure contours. To insure an accurate photographic record of the patient's anatomy, each of the five photos shown below must be taken without lip retraction or anesthesia.



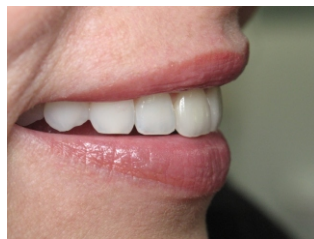**Photograph #1:** Shows the patients full face while saying "eeeeee...". Notice the lips are in a full "Say Cheese" type smile. The teeth are slightly apart making the lower incisal edges clearly visible. All of the features of the face are visible in order to align the vertical mid-line and the horizontal occlusal plane.



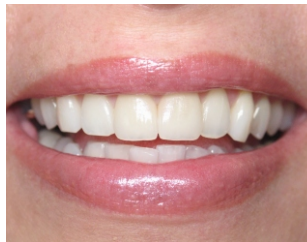**Photograph #2:** A close-up of the same facial pose as photograph #1, showing no more and no less than the corners of the lips. This photo, along with the study models, helps determine whether changes to existing anatomical features are needed such as mid-line, incisal length, curve of spee, the gingival and incisal embrasure contours and the buccal corridor.



**Photograph #3:** The "Relaxed Smile Pose". Ideally the upper lip aligns with the gingival height of the upper anterior teeth. Also, the curve of the lower lip aligns with the upper anterior incisal edges and the buccal cusp tips of the posteriors.



**Photograph # 4:** The same "Relaxed Smile Pose", as in photo #3, but taken from the side at a 75° angle to the sagittal plane. Check the labial contour and inclination, as well as incisal edge position; ideally, the incisal edges will just touch the wet-dry inner vermillion border of the lower lip.



**Photograph # 5:** Also a "Relaxed Smile Pose", but with the mandible opened just enough to allow viewing of the lower incisal edges unobscured by the upper incisal edges. Make sure you can see the lower teeth 0.5-1.5 mm above and aligned with the lower lip. This photo along with Photo#2 help with lower arch anterior design.

"These five photos combined with the mounted models and written goals provide a solid platform of success for cosmetic diagnostic wax-up. These important communication tools are needed for full-mouth rehabilitation cases to aid and simplify consultations with the lab."

Do you have a question for Steve?  
Please contact him at: [steve@killiandental.com](mailto:steve@killiandental.com)

[www.killiandental.com](http://www.killiandental.com)



D E N T A L L A B O R A T O R Y

Killian Dental Ceramics, Inc., CDL  
67 Peters Canyon Rd., Irvine, California 92606  
949-733-3111 • 800-317-7100